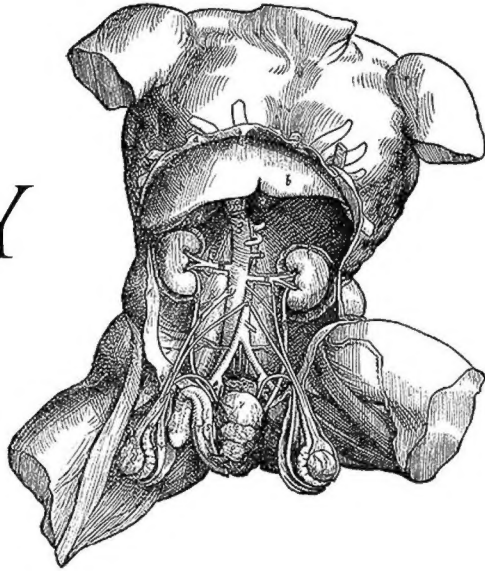


ANATOMY OF THE HUMAN BODY

PART 3

HENRY GRAY



LibriVox
www.libriVox.org

- | | |
|---|--|
| <p>01 - Angiology: Introduction
02 - The Blood
03 - Development of the Vascular System, Part 1
04 - Development of the Vascular System, Part 2
05 - The Thoracic Cavity; The Pericardium
06 - The Heart, Part 1
07 - The Heart, Part 2
08 - Peculiarities in the Vascular System in the Fetus
09 - The Arteries: Introduction
10 - The Aorta
11 - The Common Carotid Artery
12 - The External Carotid Artery, Part 1
13 - The External Carotid Artery, Part 2
14 - The Triangles of the Neck
15 - The Internal Carotid Artery
16 - The Arteries of the Brain
17 - Arteries of the Upper Extremity: The Subclavian Artery, Part 1
18 - The Subclavian Artery, Part 2
19 - The Axilla; The Axillary Artery
20 - The Brachial Artery
21 - The Radial Artery
22 - The Ulnar Artery
23 - Arteries of the Trunk: Descending Aorta; Thoracic Aorta
24 - The Abdominal Aorta, Part 1
25 - The Abdominal Aorta, Part 2</p> | <p>25 - The Abdominal Aorta, Part 2
26 - The Common Iliac Arteries
27 - The Hypogastric Artery
28 - The External Iliac Artery
29 - The Arteries of the Lower Extremity: The Femoral Artery
30 - The Popliteal Fossa; The Popliteal Artery
31 - Anterior Tibial Artery; Arteria Dorsalis Pedis
32 - The Posterior Tibial Artery
33 - The Veins: Introduction
34 - Pulmonary Veins; Systemic Veins: Veins of the Heart
35 - Veins of Head and Neck: Veins of Exterior of Head and Face
36 - Veins of the Neck
37 - The Diploic Veins; Veins of the Brain
38 - Sinuses of Dura Mater, Ophthalmic Veins, Emissary Veins
39 - Veins of Upper Extremity and Thorax
40 - Veins of Lower Extremity, Abdomen, and Pelvis, Part 1
41 - Veins of Lower Extremity, Abdomen, and Pelvis, Part 2
42 - The Portal System of Veins
43 - The Lymphatic System: Introduction
44 - The Thoracic Duct
45 - Lymphatics of the Head, Face, and Neck
46 - Lymphatics of the Upper Extremity
47 - Lymphatics of the Lower Extremity
48 - Lymphatics of the Abdomen and Pelvis, Part 1
49 - Lymphatics of the Abdomen and Pelvis, Part 2
50 - Lymphatic Vessels of the Thorax</p> |
|---|--|

Read by: Laurie Anne Walden, Julie VW, Lee Ann Howlett, Suzisinger, MorganScorpion, J.M. Smallheer, Jennifer Stearns, Celena Arter, Elli, EHehl, Neeru Iyer, Annise, Bellona Times, Rachel Gatwood, Marianne Coleman-Hipkins, David Lawrence, Carolyn Power